



**PATIENT**

Max Cardimona

**SPECIES**

Canine

**BREED**

Terrier Mix

**SEX**

MN

**AGE**

12 years

**WEIGHT**

21 lbs

**INTERPRETED BY**

Maggie Machen Lamy,  
DVM, DACVIM  
(Cardiology)

**IMAGING PERFORMED BY**

Dana Alterman,  
RDCS, LVT

**HOSPITAL NAME**

Eubank Animal Clinic

**REFERRING VET**

Dr. Grainger

**INVOICE**

25912

**DATE**

8/22/22

**PRESENTING CLINICAL SIGNS**

History: New murmur grade 2/6 systolic. 1 week history of collapsing episodes - mostly on walks with no loss of consciousness. Recent exercise intolerance owner states Max is doing worse. Today RR = 80bpm with pale MM. HW test negative 8-2022.

**RADIOGRAPHIC FINDINGS** \*NOTE: Images submitted for supplemental cardiac information only.  
Mild right-sided cardiomegaly. No obvious evidence of CHF.

**ELECTROCARDIOGRAPHIC FINDINGS** \*Note: Single lead ECGs are evaluated as a rhythm strip.  
Morphology/MEA cannot be definitively commented on.

A single lead ECG is available; 50mm/s, 20mm/mV. The average heart rate is 170bpm. The rhythm is sinus in origin, with a p for every QRS complex and vice versa. The P and QRS morphologies are positive. No ectopic beats, pauses or other dysrhythmias observed.  
ECG diagnosis: Normal sinus rhythm.

**ECHOCARDIOGRAM FINDINGS**

2D, m-mode, color flow and doppler imaging is available. Mild thickening of mitral valve leaflets with no obvious prolapse into the left atrial lumen. No mitral regurgitation with a normal left atrial dimension. Small LV diameter with adequate myocardial function. The tricuspid valve appears thickened with severe tricuspid regurgitation. Moderate right atrial enlargement; severe right ventricular dilation and hypertrophy consistent with pulmonary arterial hypertension. Septal flattening. TR velocity consistent with severe PAH. The pulmonic and aortic valves are normal in morphology and mobility. Moderate main PA and branch dilation. Hyperechoic lesion in right branch of the pulmonary artery. Mild pulmonic insufficiency. Normal pulmonic and aortic outflow velocities. No pericardial or pleural effusion. No cardiac tumors observed.

**CARDIAC CHART**

CANINE CARDIAC PARAMETERS	MR VMAX (m/s)	TR VMAX (m/s)	LA/AO (Boon method)	LA/AO (Heart Base; Swe)	FS (%)	EF (%)	EPSS (cm)
NORMAL PARAMETER	4.5-5.5	<2.7	1.3	<1.6	28-40	40-100	<0.6
PATIENT	NA	5.0	NM	1.1	50	85	NM
CANINE CARDIAC PARAMETERS	HR (BPM)	AV VMAX (m/s)	PV MAX (m/s)	BODY WEIGHT (kg)	LA 2D short axis Base view (cm)	LVIDd Avg; 2D and m-mode short axis (cm)	LVIDs Avg; 2D and m-mode short axis (cm)
NORMAL PARAMETER	50-100	0.7-1.7	0.7-1.6	BELOW	BELOW	BELOW	BELOW
PATIENT	NM	0.72	0.95	10	1.7	1.4	0.7
*Normal chamber parameters expressed as a mean value (SD)				3	1.27 (5.3)	2.46 (2.46)	1.36 (5.5)
<b>BODY WEIGHT DEPENDENT PARAMETERS</b>				5	1.40 (4.5)	2.74 (5.2)	1.60 (4.7)
*Note: All measurements based upon multi-modal images and methods. An average value is reported.				10	1.50 (3.8)	3.27 (3.5)	2.06 (3.1)
				15	1.83 (2.0)	3.71 (2.4)	2.43 (2.1)
				20	2.02 (1.9)	4.14 (2.2)	2.80 (2.0)
				25	2.18 (2.4)	4.48 (2.9)	3.10 (2.5)
				30	2.33 (3.3)	4.83 (3.9)	3.39 (3.4)
				35	2.48 (4.3)	5.17 (5.0)	3.69 (4.5)
				40	2.62 (5.2)	5.48 (6.1)	3.96 (5.4)

Adapted from June Boon, Veterinary Echocardiography, 1998  
Rishniw M and Hollis NE, J Vet Intern Med 2000; 14:429-435  
Hansson et al, Vet Rad and Ultrasound 2002  
Bonagura et al. Echocardiography: principles of interpretation, Vet Clin North Am 15:1177, 1995



**PATIENT**

Max Cardimona

**SPECIES**

Canine

**BREED**

Terrier Mix

**SEX**

MN

**AGE**

12 years

**WEIGHT**

21 lbs

**INTERPRETED BY**

Maggie Machen Lamy,  
DVM, DACVIM  
(Cardiology)

**IMAGING PERFORMED BY**

Dana Alterman,  
RDCS, LVT

**HOSPITAL NAME**

Eubank Animal Clinic

**REFERRING VET**

Dr. Grainger

**INVOICE**

25912

**DATE**

8/22/22

	50	2.88 (7.1)	6.07 (8.3)	4.46 (7.4)
--	----	------------	------------	------------

**INTERPRETATION OF THE FINDINGS & FURTHER RECOMMENDATIONS**

There is severe pulmonary hypertension (PAH) present, as evidenced by an elevated TR velocity and significant right heart compensatory changes. The estimated systolic pulmonary arterial pressure is >100mmHg, with normal being <25mmHg. The degree of hypertrophy and dilation of the right ventricle and MPA is indicative of severe right-heart pressure overload. The left heart is normal, with evidence of volume depletion. Baseline labs are recommended. Finally the ECG is unremarkable with a normal sinus rhythm.

Clinical signs of weakness, heavy breathing, cyanosis, and syncope are attributed to severe PAH. It is important to note that PAH is not the cause of a cough in these cases, rather it develops secondary to a chronic cough/labored breathing.

The underlying genesis of PAH is poorly understood in cases other than heartworm infestation, though it occurs with increased frequency in a variety of forms of chronic lung disease and in patients with idiopathic pulmonary fibrosis. Given the breed, chest x-rays are recommended with further respiratory historical information if available. Terriers are predisposed to chronic lower airway disease and if present the cough should also be addressed. Of great concern there is also a soft tissue lesion present in the right branch of the pulmonary artery. This is similar to a worm embolus in appearance; however, the patient is HW negative. Other rule outs include a thrombus, small mass or other lesion, with any a possibility. My assumption is the development of the lesion has worsened an already poor oxygenation status, given the chronicity of disease seen here (ie it is unlikely this was the sole cause of PAH/RH enlargement). Regardless, this may certainly put the patient at risk for acute worsening at any time should this lesion embolize or further occlude flow. Highly recommend referral to a multi-specialty center for further investigation of this finding (advanced imaging such as a CT scan, etc).

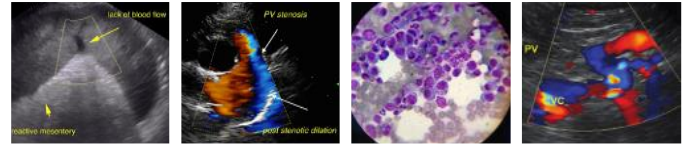
Patients with this degree of PAH can develop right-sided congestive heart failure (ascites), debilitating cyanosis, labored breathing and exertional syncope if poorly controlled. Given reported syncope, medical management with Pimobendan and Sildenafil is certainly indicated as below. If there was acute worsening of symptoms, Baytril or similar antibiotic may also be useful. As mentioned previously, adequate cough control is also key to managing these cases if present. Additionally given the lesion Plavix is reasonable with further investigation for clotting disorders, PLN, etc recommended.

Once stable, use of theophylline and/or taper course of anti-inflammatory steroids can also be beneficial in these cases, to treat exertional dyspnea or acute flare ups and decrease the inflammatory component as much as possible. PRN use of cough suppressants may also be beneficial. Unfortunately, the prognosis overall is poor, however I am hopeful we can provide some improved medical relief going forward.

Omega fatty acid supplementation (anti-inflammatory) may be of some long-term benefit. Monitor for worsening of labored breathing, exercise intolerance or collapse episodes.

**PLAN:**

Recommend referral as discussed. If declined, consider systemic evaluation including full labs, clotting times, screen for PLN, etc. Institute sildenafil 1-2mg/kg PO q8h. Institute Pimobendan at



**PATIENT**

Max Cardimona

0.3mg/kg PO q12h. Institute fluoroquinolone if indicated. Consider hydrocodone as needed up to every 4-6hours PRN for cough if indicated. Consider anti-coagulant Plavix 75mg tabs; ¼ tab PO q24h.

**SPECIES**

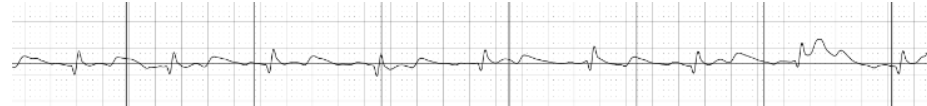
Canine

Recommend recheck echocardiogram in 6 months to reassess pulmonary pressures, sooner if any development of clinical signs.

**BREED**

Terrier Mix

**IMAGES**



**SEX**

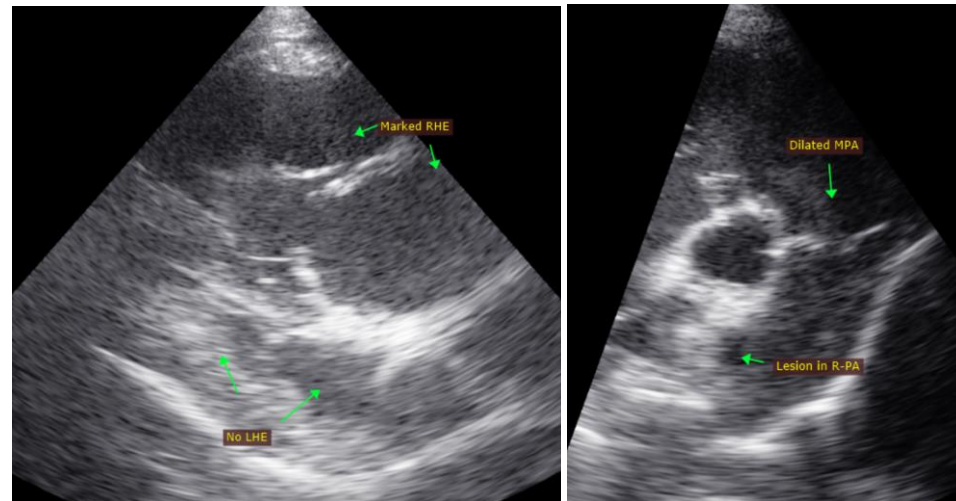
MN

**AGE**

12 years

**WEIGHT**

21 lbs



**INTERPRETED BY**

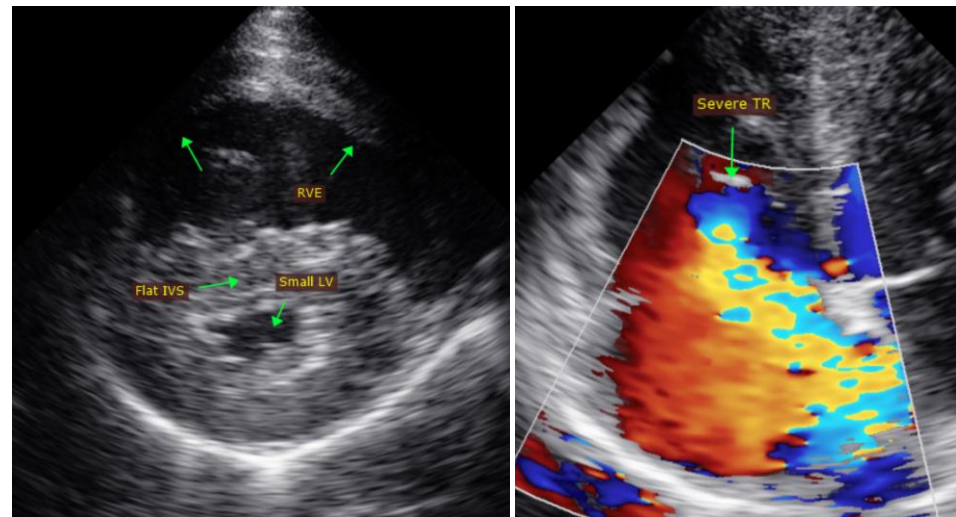
Maggie Machen Lamy,  
DVM, DACVIM  
(Cardiology)

**IMAGING PERFORMED BY**

Dana Alterman,  
RDCS, LVT

**HOSPITAL NAME**

Eubank Animal Clinic



**REFERRING VET**

Dr. Grainger

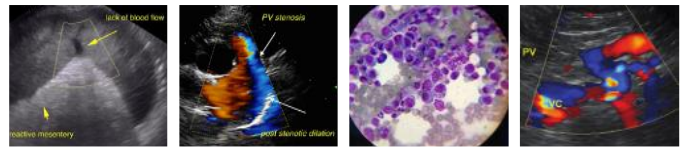
**INVOICE**

25912

The information and recommendations provided are based on the images presented by the referring veterinarian. No evaluation can be communicated regarding pathology that was not visible in the image/video clips provided.

**DATE**

8/22/22



**PATIENT**

Max Cardimona

Thank you for this referral. If the clinical or image interpretation does not parallel your findings or if I can be of any further assistance, please contact me.

**SPECIES**

Canine

**Maggie Machen Lamy, DVM**

**Diplomate of the American College of Veterinary Internal Medicine (Cardiology)**

info@sonopath.com

**BREED**

Terrier Mix

**SEX**

MN

**AGE**

12 years

**WEIGHT**

21 lbs

**INTERPRETED BY**

Maggie Machen Lamy,  
DVM, DACVIM  
(Cardiology)

**IMAGING  
PERFORMED BY**

Dana Alterman,  
RDCS, LVT

**HOSPITAL NAME**

Eubank Animal Clinic

**REFERRING VET**

Dr. Grainger

**INVOICE**

25912

**DATE**

8/22/22